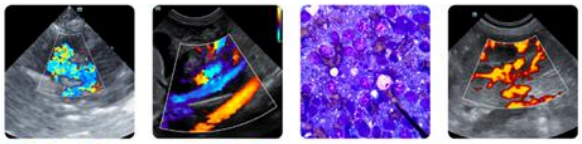

Clinical Sonography & Telecytology
Educational Teleconsultation Services™

PATIENT
Perla Papineau Feline Recsue

SPECIES
Feline

BREED
DSH

SEX
FS

AGE
2yr

WEIGHT
4.24kg

INTERPRETED BY
R. McKenzie Daniel, DVM, DABVP (Canine and Feline)

IMAGING PERFORMED BY
Natalia Franco

HOSPITAL NAME
Eagleson Veterinary Clinic

REFERRING VET
Mohamed Zaid

INVOICE
23509

DATE
01/12/2026

PRESENTING CLINICAL SIGNS

History of chronic GI issues (vomiting, diarrhea/constipation, decreased appetite) and lethargy. Historical tentative diagnosis of IBD; Patient was doing well on DM diet as per rDVM records . Distended abdomen on presentation. AUS recommended to investigate for FIP and/or IBD.

Abnormal PE/Chem/CBC/UA Results: Today: CBC/Comprehensive Chem: NSF BW performed 4d ago: mild monocytosis, mild hyperglobulinemia and mildly increased Amylase. NSF on abdominal radiographs.

ULTRASONOGRAPHIC EXAMINATION OF THE ABDOMEN

Urinary System

The urinary bladder, trigone, cystourethral junction, and visible pelvic urethra to a depth of 2 cm exhibited normal thickness and tone. Anechoic urine was present in the lumen with no evidence of urine/lumen sediment, mineral, or calculi. The ureteral papillae were normal. The ureters were not visible which is normal. No evidence of inflammatory or neoplastic changes was noted.

Normal size and margination were present in the kidneys. A normal 1:3 cortex / medulla ratio and normal corticomedullary definition were maintained. The echogenicity of the cortex was similar to or slightly less than normal liver parenchyma while the medulla echogenicity was hypoechoic to the cortex with no evidence of pelvic dilation. The left kidney measured 3.9 cm in length. The right kidney measured 3.9 cm in length.

The area of the aortic trifurcation was free of pathology.

Adrenal Glands

The left adrenal gland was uniform in size and contour with a uniformly hypoechoic parenchyma. The left adrenal gland measured 0.4 cm width. The right adrenal gland was uniform in size and contour with a uniformly hypoechoic parenchyma. The right adrenal gland measured 0.4 cm width.

Spleen

The spleen exhibited a finely textured and homogenous parenchyma which was hyperechoic to the liver and renal cortical parenchyma. The capsule was smooth and regular without apparent expansion. The splenic vasculature at the hilus was normal in volume with no evidence of congestion or thrombosis. Acute to chronic inflammatory, neoplastic, or benign parenchyma changes were not noted. The spleen measured 0.9 cm in width at the level of the mid spleen.

Liver/Gallbladder

The liver was subjectively normal in size, structure, and contour. The liver parenchyma was uniform and hypoechoic to the spleen with a mild coarse echotexture. Normal vascular volume. The hepatic and portal vasculature were normal in appearance without signs of congestion. The gallbladder was non-distended in size with thin walls and primarily anechoic luminal content. The cystic and common bile ducts were normal.

Gastrointestinal

The stomach presented intact wall layering with a normal wall layer ratio. The lumen of the stomach was empty with no signs of ileus, obstruction or foreign material.

PATIENT
Perla Papineau Feline Recsue

SPECIES
Feline

BREED
DSH

SEX
FS

AGE
2yr

WEIGHT
4.24kg

INTERPRETED BY
R. McKenzie Daniel, DVM, DABVP (Canine and Feline)

IMAGING PERFORMED BY
Natalia Franco

HOSPITAL NAME
Eagleson Veterinary Clinic

REFERRING VET
Mohamed Zaid

INVOICE
23509

DATE
01/12/2026

The intestinal walls demonstrated intact wall layers with mild thickened walls and altered 1:3 muscularis / mucosa ratio primarily consisting of mild muscularis hypertrophy.

Normal visible colon wall layers were present with current semi formed feces in lumen.

Pancreas

The parenchyma of the left limb, body and right limb of the pancreas presented isoechoic to the adjacent omental fat. A normal curvilinear capsule contour of the pancreas was present. The visible pancreatic duct was normal. No signs of active inflammation or neoplastic disease was evident.

Free Abdomen

No omental masses, overt lymphadenopathy or peritoneal effusion was present.

Generalized normal omental echogenicity was present.

ULTRASONOGRAPHIC FINDINGS

Primary

- Intact mildly thickened small intestine with generalized empty gastrointestinal tract
- Sonographically unremarkable area of pancreas
- Normal peritoneal cavity.

INTERPRETATION OF THE FINDINGS & FURTHER RECOMMENDATIONS

No evidence of gastrointestinal mechanical obstruction i.e. FB or masses with primarily mild intestinal mural changes suggestive of inflammatory enteropathy criteria i.e. IBD. Potential for emerging intestinal neoplasia or FIP is thought less likely. Mild pancreatitis may present sonographically normal.

A GI panel to include PLI/TLI/Cobalamin/Folate may be considered. Intestinal biopsies would be required for a definitive diagnosis. Empirical IBD protocol and gastrointestinal support with clinical and as needed sonographic monitoring if persistent clinical signs or weight loss would be reasonable.

SonoPath
FOSTERING THE ART OF VETERINARY MEDICINE™

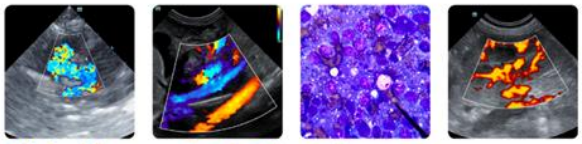

Clinical Sonography & Telecytology
Educational Teleconsultation Services™

SonoPath.com info@sonopath.com 1.800.838.4268

PATIENT

Perla Papineau Feline Recsue

SPECIES

Feline

BREED

DSH

SEX

FS

AGE

2yr

WEIGHT

4.24kg

INTERPRETED BY

R. McKenzie Daniel, DVM, DABVP (Canine and Feline)

IMAGING PERFORMED BY

Natalia Franco

HOSPITAL NAME

Eagleson Veterinary Clinic

REFERRING VET

Mohamed Zaid

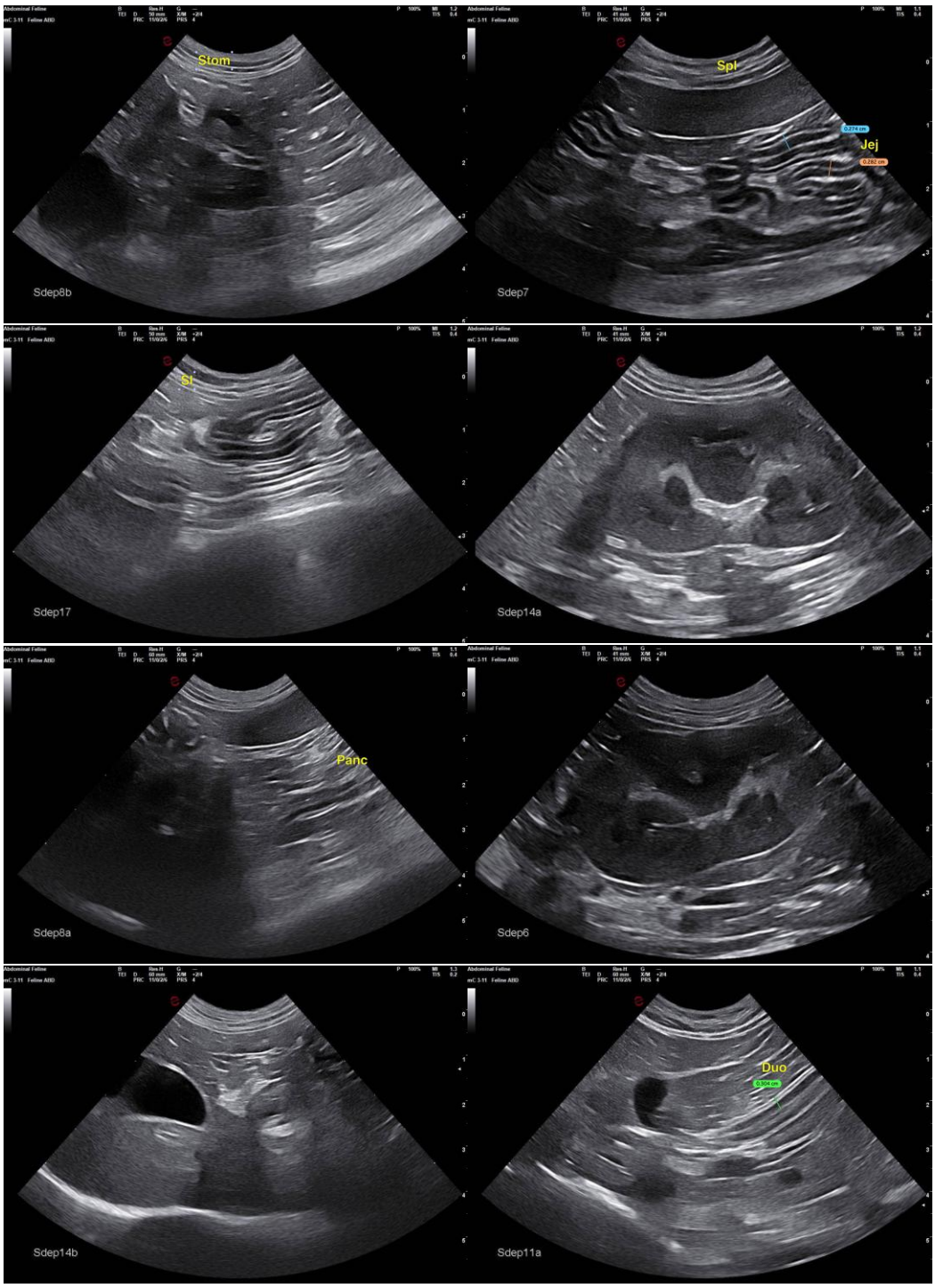

INVOICE
23509

DATE
01/12/2026

The information and recommendations provided are based on the images presented by the referring veterinarian/sonographer. No evaluation can be communicated regarding pathology that was not visible in the image/video clips provided.

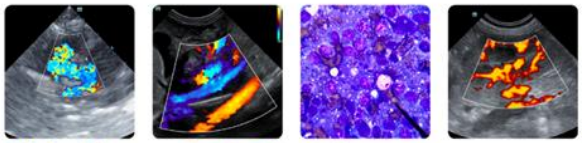

PATIENT

Perla Papineau Feline Recsue

SPECIES

Feline

BREED

DSH

SEX

FS

AGE

2yr

WEIGHT

4.24kg

INTERPRETED BY

R. McKenzie Daniel, DVM, DABVP (Canine and Feline)

IMAGING PERFORMED BY

Natalia Franco

HOSPITAL NAME

Eagleson Veterinary Clinic

REFERRING VET

Mohamed Zaid

INVOICE
23509

DATE
01/12/2026

Thank you for this referral. If the clinical or image interpretation does not parallel your findings or if I can be of any further assistance, please contact me.

R. McKenzie Daniel, DVM, DABVP (Canine/Feline Practice)
info@sonopath.com